



Safety of PEGylated Hyaluronic Acid Filler for the Treatment of Facial Skin Aging: Case Report

Kubik P* and Gruszczyński W

K-LAB Badania I Rozwój, 81-312 Gdynia, Poland

Abstract

Background: The face is the area most exposed to the normal course of skin aging, both intrinsically and extrinsically.

Aim: The aim of the case report was to evaluate the cellular and clinical response of a therapeutic protocol aimed at countering facial skin aging.

Materials and Methods: One female patient with facial skin laxity and photodamage underwent treatment protocol of implementation of PEG-cross-linked hyaluronic acid soft tissue fillers.

Results: The histological results at 0, 7, 14 and 21 days after the procedure showed an increase in the number of fibroblasts and angiogenesis, at the same time it was shown that the treatment has an immunomodulating action.

Conclusion: A treatment with PEG-cross-linked hyaluronic acid leads to numerous positive cutaneous changes after histological and immunological evaluations.

Keywords: HA PEGylated filler; PEG-cross-linked hyaluronic acid; Facial skin aging

Introduction

Hyaluronic acid injectable fillers are the most widely used dermal fillers to treat facial volume deficits, providing long-term facial aesthetic enhancement outcomes for the signs of aging and/or facial contouring. Aesthetic medicine treatments using both cross-linked and non-cross-linked hyaluronic acid are currently one of the most frequently performed treatments. Soft tissue fillers are the leading materials used in aesthetic medicine to rebuild soft tissue atrophy of both the face and other parts of the body. Hyaluronic acid is in the form of a gel, and the products available on the market differ in a wide range of density and viscosity, rheological properties and concentration. This allows for the optimal selection of the product used depending on the intended use, the anatomical area undergoing treatment, the depth of application or the technique adopted by the doctor performing the procedure and the individual needs of the patient.

A way to extend the effect of hyaluronic acid is to subject it to the cross-linking process. Cross-linking in fillers based on hyaluronic acid is a process that allows the linear chain of hyaluronic acid to be given a three-dimensional structure by creating covalent bonds between hyaluronic acid and the cross-linking agent. This process improves the physicochemical properties of hyaluronic acid while maintaining the biocompatibility and biological activity of the resulting soft tissue filler [1].

Currently, the most commonly used cross-linking agents in the production of soft tissue fillers are Butanediol Diglycidyl Ether (BDDE), 1,8-Diepoxyoctane (DEO), Divinyl Sulfone (DVS) and Polyethylene Glycol Diglycidyl Ether (PEGDE). The technologies used in this process of cross-linking hyaluronic acid vary depending on the manufacturer, they differ in the degree of cross-linking, the amount of cross-linking agent used and the concentration of hyaluronic acid itself. Modifications resulting from cross-linking significantly affect the rheological properties of the resulting gels, which also affect the aesthetic effect [2].

Treatments using soft tissue fillers have become more and more popular since the late 1990s, and due to their more frequent use, we are also faced with more and more frequent side effects, including serious ones. Adverse events related to the use of fillers can be divided into four categories: allergic, infectious, late-onset nodules/inflammation and intravascular events [3,4]. The choice of fillers based on hyaluronic acid, apart from such obvious issues as in-depth knowledge of anatomy, appropriate procedure technique, and, of course, a patient assessment, becomes one of the key

OPEN ACCESS

***Correspondence:**

Paweł Kubik, K-LAB Badania I Rozwój,
81-312 Gdynia, Poland,

Received Date: 16 Mar 2024

Accepted Date: 15 Apr 2024

Published Date: 20 Apr 2024

Citation:

Kubik P, Gruszczyński W. Safety of PEGylated Hyaluronic Acid Filler for the Treatment of Facial Skin Aging: Case Report. *Clin Case Rep Int.* 2024; 8: 1679.

Copyright © 2024 Kubik P. This is an open access article distributed under the Creative Commons Attribution License, which permits unrestricted use, distribution, and reproduction in any medium, provided the original work is properly cited.

factors that can minimize the risk of undesirable effects and have a positive impact on the safety profile of the procedure. The latest innovation in the production and cross-linking of hyaluronic acid is the use of Polyethylene Glycol (PEG) polymer. It appears that the use of PEG may offer significant benefits in terms of safety and the performance of a hyaluronic acid-based gel.

Both the cross-linking agent PEG and hyaluronic acid are polymers, and their cross-linking allows the creation of matrices with a scaffolding structure resembling a three-dimensional network, thus ensuring better integration of the filler with the tissue [5-7]. Thanks to cross-linking with PEG, the resulting soft tissue filler is characterized by excellent rheological properties, such as cohesivity, viscoelasticity and plasticity, with optimized adaptation and integration with anatomical structures [8-10].

Here, we reported 1 case of patient undergoing soft tissue filler monotherapy using PEGylated hyaluronic acid filler with a 1% addition of calcium hydroxyapatite.

Case Presentation

A healthy 60-year-old female during one session underwent filler procedure to lift and restore lack of volume of subcutaneous tissue with Neuvia Stimulate (Matex Lab, Geneva, Switzerland). Skin biopsy was taken before the procedure from the preauricular area, then on day 0, 7, 14 and 21 after the procedure. The patient who underwent the therapy for skin laxity, confirmed improvement of skin elasticity by subjective measurements of skin elasticity, and detailed histopathological tests. Histopathological tests were to determine detailed tissue reactions that stand behind the results.

The patients underwent the following protocol:

Day 0: Injection of 2.0 cc of Neuvia Stimulate; malar area—dermal.

The patient had a hyaluronic acid filler procedure with Neuvia Stimulate (MatexLab, Geneva, Switzerland), which is a soft tissue filler based on HA crosslinked with PEG (26 mg/ml), with addition of 1% calcium hydroxyapatite, glycine and l-proline. It is an injectable medical device indicated for the temporary correction of the sign of primary soft tissue senile atrophy of the face [11].

The patient has signed a written informed consent document. The case report was conducted in accordance with the Declaration of Helsinki, and approved by the Ethics Committee of Okręgowa Izba Lekarska w Gdańsku (protocol code 1/CMDRK/2020 in 27 October 2020). Skin biopsies from the patient were obtained from the preauricular area at day 0, 7, 14 and 21. All samples were submitted for independent assessment to the Clinical Pathomorphological Department of the Nicolaus Copernicus University, Toruń, Poland.

Microscopic analysis of Hematoxylin and Eosin (HE)-stained skin biopsies was performed, histochemical staining of Masson's Trichrome and immunohistochemistry was performed using an ECLIPSE E400 light microscope (NIKON), with a 10x and 20x lens. Hematoxylin-eosin staining was used to assess the overall tissue structure by contrast staining the cytoplasm and cell nuclei. The inflammatory infiltrate was assessed on a scale of 0-4 and the mononuclear cells present in it (0 - none; 1 - they constitute up to 25% of the inflammatory infiltrate; 2 - they constitute from 26-49% of the inflammatory infiltrate; 3 - they constitute from 50-75% inflammatory infiltrate; 4 - constitute from 76-100% of the inflammatory infiltrate). Masson's trichrome staining (Special Stain Kit Masson's Trichrome, DiaPath, Martinengo, Italy) was used to assess collagen on a scale (0 - loose, regular; 1 - loose, irregular; 2 - dense; 3 - compact, thick fibers).

Immunohistochemical examination was performed to detect CD4, CD8, CD 34, CD68, and PAX5 antigens. The study was conducted using mono- or polyclonal rabbit or mouse antibodies. The expression of CD4, CD8, CD 34 and CD68 proteins was assessed on a scale (0-100% of inflammatory cells).

Results

A 60-year-old female patient with facial skin laxity and photodamage underwent soft tissue filler treatment with histological examinations to determine the safety and tissue response after this a procedure. We reported histologic findings related to aesthetic procedure with the usage of PEGylated hyaluronic acid filler. As a result, after the procedure, the patient's skin showed substantial improvements in terms of skin topography to a greater extent than just facial rejuvenation. Histologic findings correlated magnificently with the skin. Skin biopsies taken from this patient were selected for detailed histological examinations to determine the mechanisms behind the changes developing after the soft tissue filler injection. Histopathological samples taken from the treatment areas were used to evaluate changes in inflammatory infiltration (generally using H&E staining (presence of mononuclear cells) detailed by immunohistochemistry: CD4, CD8, CD 34, CD68, PAX5. Followed by tissue rejuvenation detailed by Vimentin presence, and collagen Masson's trichrome staining. Below we present the collected results (Figures 1-7).

Day 0 results

- H&E staining revealed normal tissue structure, without inflammatory infiltration
- Masson's Trichrome staining revealed single collagen fibers (0 - loose, regular)
- CD34 – positive reaction

Day 7 results

- H&E staining revealed numerous proliferating fibroblasts

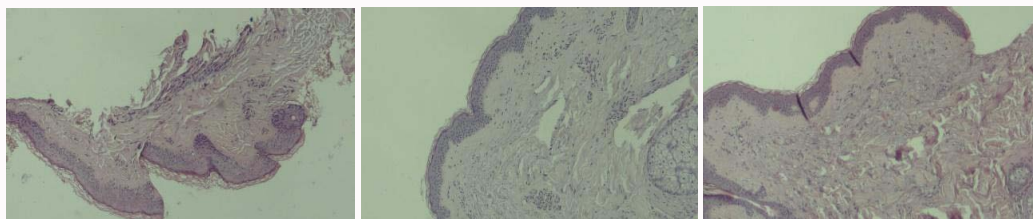


Figure 1: Hematoxylin-eosin staining. From left: before treatment, 14 days after treatment, 21 days after treatment.




Figure 2: Comparison of CD4 expression. From left: 7 days after treatment, 14 days after treatment, 21 days after treatment.



Figure 3: Comparison of CD8 expression. From left: 7 days after treatment, 14 days after treatment, 21 days after treatment.



Figure 4: Comparison of CD34 expression. From left: before treatment, 14 days after treatment, 21 days after treatment.

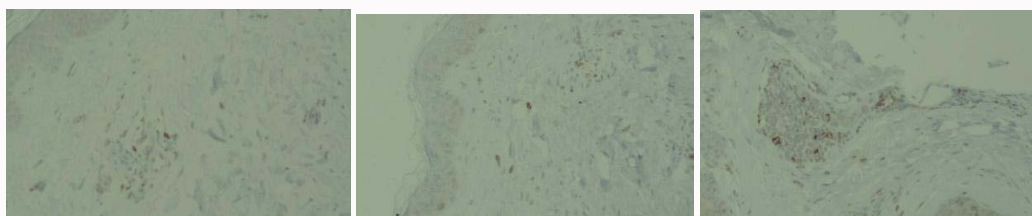


Figure 5: Comparison of CD68 expression. From left: 7 days after treatment, 14 days after treatment, 21 days after treatment.




Figure 6: Comparison of PAX5 expression. From left: 7 days after treatment, 14 days after treatment, 21 days after treatment.

with large nuclei and a small, slightly basophilic fragment of amorphous substance, which may correspond to a fragment of hyaluronic acid

- Trichrome Masson staining revealed individual collagen fibers (0 - loose, regular)
- CD4 – positive reaction in single cells
- CD34 – positive reaction in vascular endothelium and proliferating fibroblasts

- CD8, CD4, PAX5, CD68 – positive reaction in single cells (few)

Day 14 results

- H&E staining revealed inflammatory infiltrate (on a scale of 0-5: 2), located mainly around the vessels, and proliferating fibroblasts. Smaller fragments of amorphous substance are found, which may correspond to hyaluronic acid or newly formed/ degenerating collagen

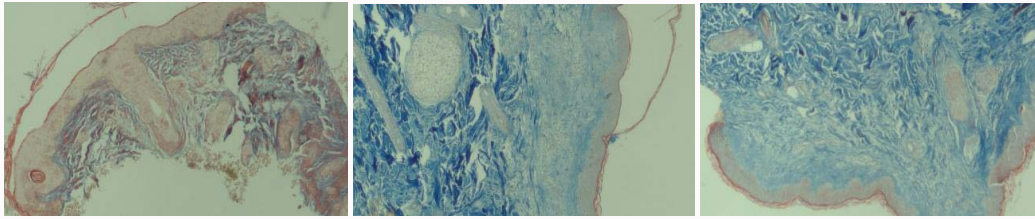


Figure 7: Collagen expression. From left: before treatment, 14 days after treatment, 21 days after treatment.

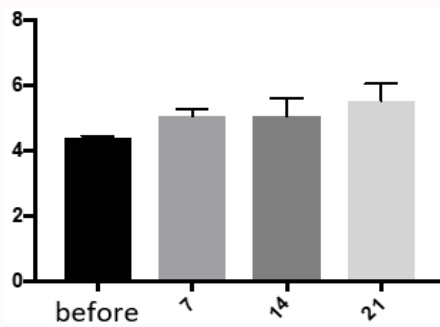


Chart 1: Fluorescence intensity. From left: before treatment, 14 days after treatment, 21 days after treatment.

Table 1: Statistical analysis results for collagen fluorescence intensity.

Before vs. 7 days after procedure	15.9%	p value 0.2491
Before vs. 14 days after procedure	17.0%	p value 0.2294
Before vs. 21 days after procedure	27.3%	p value 0.0313

- Trichrome Masson staining revealed numerous collagen fibers (1 - loose, irregular)
- CD34 – positive reaction in vascular endothelium and proliferating fibroblasts
- CD8, CD4, PAX5, CD68 positive reaction in single cells (few)

Day 21 results

- H&E staining revealed a small inflammatory infiltrate (on a scale of 0-5: 1), located mainly around the vessels. There is a decrease in the number of proliferating fibroblasts compared to sections taken on day 14
- Trichrome Masson staining revealed numerous collagen fibers in the dermis (2 – dense)
- CD34 – positive reaction in vascular endothelium and proliferating fibroblasts,
- CD8 – single around vessels
- CD4 – weakly positive reaction in single cells of the inflammatory infiltrate
- CD68 – positive reaction in numerous macrophages
- PAX5 – positive reaction in single cells of the inflammatory infiltrate

In the case of unstained skin samples, fluorescence analysis in the red channel showed significant statistical changes in collagen fluorescence intensity in accordance with the chart (Chart 1) and table (Table 1).

Discussion

In recent years, the injectable soft tissue fillers have become an increasingly popular option because of its versatility and promising results. Hyaluronic acid fillers were and are considered safe and well tolerated, recent reports may indicate unexpected safety concerns related to their immunological effects [12-16]. This case we have showed the safety of minimally invasive procedure with PEGylated hyaluronic acid filler which is widely used in the aesthetic clinics.

Histological results 21 days after the procedure showed an interesting cause and effect relationship: An increase in the number of fibroblasts/collagen and inflammation reaction in the tissues. Such response is expected both due to tissue trauma associated with the procedure - skin damage and the introduction of a foreign body - in our case PEGylated dermal filler which can also mechanically support the physiological collagenesis. Although we see that the inflammatory process has slightly intensified post-treatment, the expression levels of CD8 (T-cells), CD34, CD68 and inflammatory infiltration tend to decrease in severity over time. This phenomenon must be connected with the use and introduction of soft tissue filler based on PEGDE-HA into the tissue. The soft tissue filler used by us contained, in addition to water and PEGDE cross-linked hyaluronic acid, also an admixture of glycine and L-proline. Based on our observations and other studies, it can be concluded that the PEG used in these products (used as a cross-linking agent) has an immunomodulatory effect, limiting the inflammatory response at the site of application [17,18]. This observation after 21 days correlates with the results obtained by us in the 150-day observation of both healthy patients and patients with Hashimoto's disease who were treated with PEGDE-HA fillers [19,20].

This seems to be a very important observation for every doctor performing aesthetic procedures regarding the potential risks associated with long-term stay of a foreign body, e.g. soft tissue filler based on hyaluronic acid, and potential side effects such as granulomas and other immunological reactions.

In our case report, we observed only a short-term trend of local inflammatory infiltration and local reaction to the administration of tissue filler. However, these 21-day observations are consistent with our previous research. This suggests the possibility of an immunomodulatory effect of PEG cross-linking, which reduces local inflammation [18,19]. Research results on the ability of PEGylated hyaluronic acid gel to modulate human immune functions suggest that they carry a very low risk of immunological side effects, especially granulomatous reactions [21].

Conclusion

Due to the constantly growing popularity of aesthetic medicine treatments, including those using hyaluronic acid dermal fillers, the selection of the appropriate product is one of the key factors

influencing the safety of the procedure. Based on our observations, we can conclude that the choice of fillers based on hyaluronic acid cross-linked with polyethylene glycol should be considered as safe. The evolution of inflammatory infiltrate may result from the immunomodulatory effect of polyethylene glycol. This effect has a very positive impact on the safety profile of the treatment itself and the context of using the hyaluronic acid filler itself, both in the short and long term [19-21].

The results of the presented case report seem to be interesting and important from the point of view of the risks resulting from short and long-term effect of the hyaluronic acid implant in the skin.

These observations should also be extended and compared with other procedures used in aesthetic medicine to better understand the mechanism of immune reactions in patients using aesthetic procedures. In the future, further research will be necessary, enlargement of the sample, longer follow-up and the influence of other factors specific to the subject should be the subject of further observations.

References

1. Khunmanee S, Jeong Y. Crosslinking method of hyaluronic-based hydrogel for biomedical applications. *J Tissue Eng*. 2017;8:2041731417726464.
2. Pierre S, Liew S, Bernardin A. Basics of dermal filler rheology. *Dermatol Surg*. 2015;41:120-6.
3. Signorini M, Liew S, Sundaram H, De Boule KL, Goodman GJ, Monheit G, et al. Global aesthetics consensus: Avoidance and management of complications from hyaluronic acid fillers-evidence-and opinion-based review and consensus recommendations. *Plast Reconstr Surg*. 2016;137:961-71.
4. Bailey SH, Cohen JL, Kenkel JM. Cosmetic medicine review article: Etiology, prevention, and treatment of dermal filler complications. *Aesthetic Surg J*. 2011;31:110-21.
5. Leach JB, Schmidt CE. Characterization of protein release from photocrosslinkable hyaluronic acid-polyethylene glycol hydrogel tissue engineering scaffolds. *Biomaterials*. 2005;26(2):125-35.
6. Hassan W, Dong Y, Wang W. Encapsulation and 3D culture of human adipose-derived stem cells in an in-situ crosslinked hybrid hydrogel composed of PEG-based hyperbranched copolymer and hyaluronic acid. *Stem Cell Res Ther*. 2013;4(2):32.
7. Aurand ER. The characterization of hyaluronic acid and polyethylene glycol hydrogels for neural tissue engineering. *Neuroscience and Biomedical Engineering Thesis, University of Colorado, Denver, Anshutz Medical Campus* 2014. p. 172.
8. Zerbinati N, D'Este E, Farina A, Rauso R, Cherubino M, Calligaro A. Morphological evidences following pegylated filler treatment in human skin. *J Biol Regul Homeost Agents*. 2017;31(2 Suppl. 2):79-85.
9. Zerbinati N, Esposito C, Cipolla G, Calligaro A, Monticelli D, Martina V, et al. Chemical and mechanical characterization of hyaluronic acid hydrogel cross-linked with polyethylen glycol and its use in dermatology. *Dermatol Ther*. 2020;33(4):e13747.
10. Zerbinati N, Sommatis S, Maccario C, Capillo MC, Grimaldi G, Alonci G, et al. toward physicochemical and rheological characterization of different injectable hyaluronic acid dermal fillers cross-linked with polyethylene glycol diglycidyl ether. *Polymers (Basel)*. 2021;13(6):948.
11. Zerbinati N, Lotti T, Monticelli D, Rauso R, González-Isaza P, D'Este E, et al. *In vitro* evaluation of the biosafety of hyaluronic acid PEG cross-linked with micromolecules of calcium hydroxyapatite in low concentration. *J Med Sci*. 2018;6(1):15-19.
12. Owczarzyk-Saczonek A, Zdanowska N, Wygonowska E, Placek W. The immunogenicity of hyaluronic acid fillers and its consequences. *Clin Cosmet Investig Dermatol*. 2021;14:921-34.
13. Bitterman-Deutsch O, Kogan L, Nasser F. Delayed immune mediated adverse effects to hyaluronic acid fillers: Report of five cases and review of the literature. *Dermatol Rep*. 2015;7:5851.
14. Friedman PM, Mafong EA, Kauvar AN, Geronemus RG. Safety data of injectable nonanimal stabilized hyaluronic acid gel for soft tissue augmentation. *Dermatol Surg*. 2002;28:491-4.
15. Artzi O, Cohen JL, Dover JS, Suwanchinda A, Pavicic T, Landau M, et al. Delayed inflammatory reactions to hyaluronic acid fillers: A literature review and proposed treatment algorithm. *Clin Cosmet Investig Dermatol*. 2020;13:371-8.
16. Artzi O, Loizides C, Verner I, Landau M. Resistant and recurrent late reaction to hyaluronic acid-based gel. *Dermatol Surg*. 2016;42:31-7.
17. Knopf-Marques H, Pravda M, Wolfova L, Velebny V, Schaaf P, Vrana NE, et al. Hyaluronic acid and its derivatives in coating and delivery systems: Applications in tissue engineering, regenerative medicine and immunomodulation. *Adv Healthc Mater*. 2016;5:2841-55.
18. Marino F, Cosentino M, Legnaro M, Luini A, Sigova J, Mocchi R, et al. Immune profile of hyaluronic acid hydrogel polyethylene glycol crosslinked: An *in vitro* evaluation in human polymorphonuclear leukocytes. *Dermatol Ther*. 2020;33(3):e13388.
19. Kubik P, Jankau J, Rauso R, Galadari H, Protasoni M, Gruszczyński W, et al. HA PEGylated filler in association with an infrared energy device for the treatment of facial skin aging: 150 Day follow-up data report. *Pharmaceuticals (Basel)*. 2022;15(11):1355.
20. Kubik P, Gallo D, Tanda ML, Jankau J, Rauso R, Gruszczyński W, et al. Evaluation of the safety of Neauvia stimulate injectable product in patients with autoimmune thyroid diseases based on histopathological examinations and retrospective analysis of medical records. *Gels*. 2023;9(6):440.
21. Rauso R, Nicoletti GF, Bove P, Rauso GM, Fragola R, Lo Giudice G, et al. Clinical experience with PEGylated hyaluronic acid fillers: A 3-year retrospective study. *Open Access Maced J Med Sci*. 2021;9(B):1168-73.